

Cystoid and Diabetic Macular Edema Treated with Nepafenac 0.1%

SEENU M. HARIPRASAD,¹ DAVID CALLANAN,² STEVEN GAINNEY,³
YU-GUANG HE,⁴ and KEITH WARREN⁵

ABSTRACT

Cystoid macular edema (CME), a common complication following cataract surgery, is routinely medically treated with topical nonsteroidal anti-inflammatory drugs (NSAIDs), alone or in combination with steroids. In this paper, we describe 6 patients with CME and 1 patient with diabetic macular edema (DME), all of whom were treated with nepafenac 0.1%, a novel prodrug NSAID. Three (3) patients with acute CME following cataract surgery were treated for 3–4 weeks with nepafenac 0.1%, with or without concomitant steroids. Both retinal thickness and visual acuity improved in all 3 cases. The 3 patients with chronic CME, each of whom had been previously treated with steroids with or without concomitant NSAID therapy, were started on nepafenac 0.1% three times daily. Retinal thickness and visual acuity improved in each case, except for 1 patient with 20/25 pretreatment visual acuity. The mean improvement in visual acuity of all 6 CME patients was 2.5 lines and the mean decrease in retinal thickness was 282.8 μm . The patient with DME also showed improvement in retinal thickness and visual acuity after 6 months of treatment with nepafenac. These clinical data strongly suggest that nepafenac 0.1% is a promising drug for the treatment of posterior segment inflammation, including CME, and warrants further investigation.

INTRODUCTION

ALTHOUGH THE INCIDENCE of cystoid macular edema (CME) following cataract surgery varies widely in the literature, it has been recognized as a postoperative complication for over 50 years; the most recent clinical study of CME reported an incidence of 9% of uncomplicated cataract cases.¹ Furthermore, CME is the most frequent cause of poor vision following cataract surgery.² Recent advances in intraocular lens

focal, refractive lens implantation, which has elevated patient and surgeon expectations of postoperative visual outcomes. As a consequence, the blurred or decreased central vision that often arises from CME can result in extreme patient dissatisfaction. Furthermore, the cost of treating CME is not trivial; a recent analysis of Medicare recipients found that in the year following cataract surgery, patients with CME filed claims worth almost \$3,300 more than patients without a diagnosis of CME.³

CME is routinely medically treated with topical

¹Department of Ophthalmology and Visual Science, University of Chicago, Chicago, IL.

²Texas Retina Associates, Dallas, TX.

³Eye Clinic of Manitowoc, Manitowoc, WI.

⁴Department of Ophthalmology, University of Texas Southwestern Medical School, Dallas, TX.

⁵Department of Ophthalmology, Kansas University School of Medicine, Kansas City, KS.

nonsteroidal anti-inflammatory drugs (NSAIDs), alone or in combination with steroids, such as prednisolone acetate, despite the fact that none of the approved NSAIDs currently have indications for the treatment of CME. Clinical studies have demonstrated the ability of topical NSAIDs to reduce the duration and severity of CME,⁴⁻⁶ and their prophylactic use has even been shown to reduce the postoperative risk of developing this condition.^{7,8} Guidelines for the use of NSAID therapy associated with cataract surgery recommend that prophylaxis begin 1–2 days preoperatively for most patients and 1 week preoperatively for at-risk patients; recommended postoperative use ranges from 3 to 4 weeks (for not at-risk patients) to several months (for at-risk patients).⁹ The following cases demonstrate the usefulness of nepafenac 0.1% (Nevanac®; Alcon Labs, Fort Worth, TX) for the treatment of both acute and chronic macular edema.

CASE REPORTS

In this paper, we describe 6 patients with CME: 3 with acute CME following cataract surgery and 3 with chronic macular edema. Uncorrected log-MAR visual acuity and retinal thickness using optical coherence tomography (OCT) was measured at pre- and post-treatment (with nepafenac 0.1%) time points (Table 1). In each acute case, a diagnosis of clinical CME was made using OCT at a postoperative visit and treatment with nepafenac 0.1% with or without concomitant steroids was initiated. After 3–4 weeks of treatment, both retinal thickness and visual acuity were improved in

all cases. The 3 cases of chronic CME had been previously treated with steroids with or without concomitant NSAID therapy (i.e., using NSAIDs other than nepafenac 0.1%). Upon failure with these regimens, the patients were started on nepafenac 0.1% alone three times daily. In each of the cases, retinal thickness and visual acuity improved (except in the case of 1 patient, who had 20/25 vision before treatment with nepafenac despite having CME). Overall, the mean improvement in visual acuity was 2.5 lines and the mean decrease in retinal thickness was 282.8 μm .

Patient #1: Acute CME following cataract surgery

A 67-year-old male underwent uncomplicated cataract extraction and intraocular lens (IOL) implantation in the left eye. At 4 weeks postoperative, the patient reported blurred central vision. Visual acuity was 20/50. An examination revealed a well-centered IOL and clinical CME (retinal thickness of 342 μm). The patient was treated with nepafenac 0.1% and prednisolone three times daily for 3 weeks. Upon examination 6 weeks later, visual acuity had improved to 20/25 and retinal thickness had decreased to 193 μm (Fig. 1).

Patient #4: Chronic CME following cataract surgery

A 69-year-old female underwent cataract extraction and IOL implantation in the right eye. Two (2) months postoperative, she developed CME, which failed to respond to treatment with

TABLE 1. VISUAL ACUITY AND RETINAL THICKNESS BEFORE AND AFTER TREATMENT WITH NEPAFENAC 0.1% FOR CYSTOID MACULAR EDEMA (CME)

Patient	Before nepafenac 0.1%		After nepafenac 0.1%		Overall improvement	
	Visual acuity	Retinal thickness (μm)	Visual acuity	Retinal thickness (μm)	Lines improvement	Retinal thickness decrease (μm)
<i>Acute CME</i>						
1	20/50	342	20/25	193	3	149
2	20/30	537	20/20	214	1.5	323
3	20/70	584	20/50	361	1.5	223
<i>Chronic CME</i>						
4	20/60	690	20/30	262	3	428
5	20/25	346	20/25	227	0	119
6	20/100	689	20/25	234	6	455
Mean	—	531.3	—	248.5	2.5 lines	282.8

Note. Patient #1 was treated with prednisolone in addition to nepafenac 0.1%.

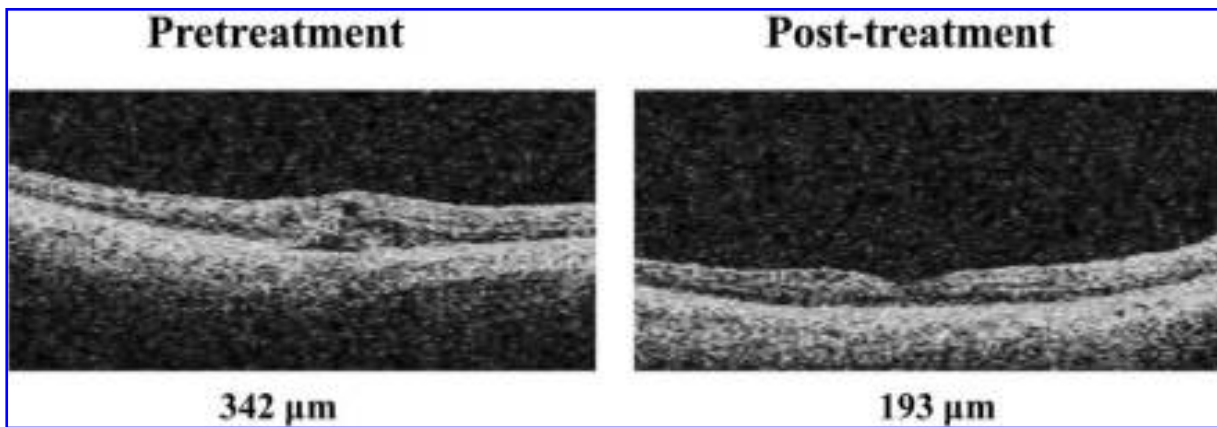


FIG. 1. Patient 1: Acute cystoid macular edema. Ocular coherence tomography images before and after treatment with nepafenac 0.1% and prednisolone three-times daily for 3 weeks.

ketorolac 0.5% and prednisolone over a 6-month period. An examination after treatment failure revealed a retinal thickness of $690\ \mu\text{m}$ and visual acuity of 20/60. Ketorolac and prednisolone were discontinued and the patient was treated subsequently with nepafenac 0.1% three times daily. After 6 weeks of treatment with nepafenac 0.1%, retinal thickness had declined to $262\ \mu\text{m}$ and visual acuity improved to 20/30 (Fig. 2).

In this paper, we also describe a 7th patient, who was diagnosed with diabetic macular edema (DME). This 66-year-old male had a pretreatment visual acuity in the left eye of 20/70 and a retinal thickness of $378\ \mu\text{m}$. After 6 months of treatment with nepafenac 0.1%, visual acuity improved to 20/40 and retinal thickness declined to $215\ \mu\text{m}$ with normal foveal contour.

DISCUSSION

Nepafenac 0.1% is a novel NSAID that is currently approved for the treatment of pain or inflammation associated with cataract surgery. Nepafenac inhibits cyclooxygenase and is the only ocular NSAID with a prodrug structure; intraocular hydrolases convert nepafenac to the more active metabolite, amfenac.¹⁰ These hydrolases are present in ocular tissues, such as the cornea and iris/ciliary body, but are at their highest concentrations in the retina/choroid. As a result, the more active form of the drug, amfenac, is effectively targeted to the inflamed macula in cases of CME.

CME is a common risk for patients following cataract surgery, leading to frustration for both pa-

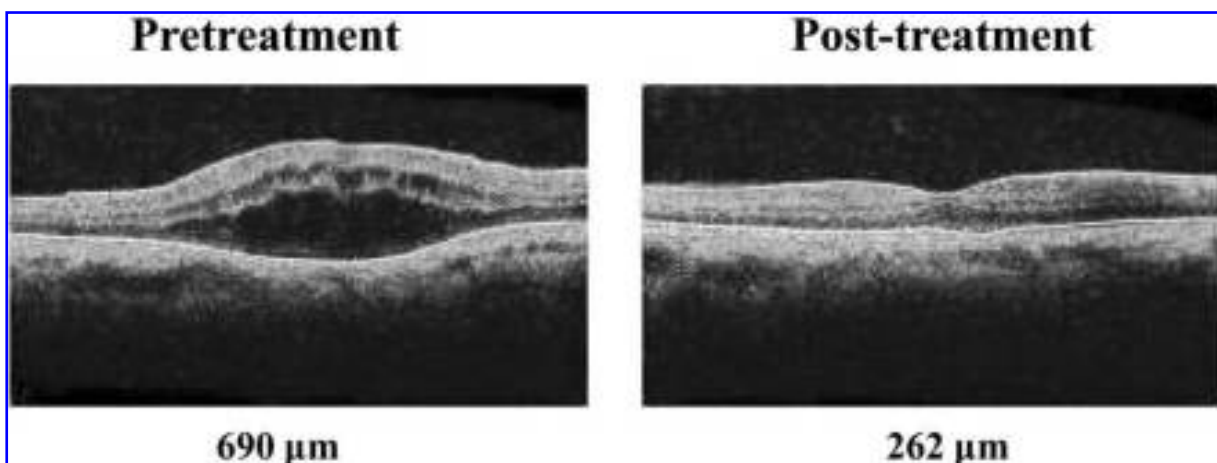


FIG. 2. Patient 4: Chronic cystoid macular edema. Ocular coherence tomography images before and after treatment with nepafenac 0.1% three-times daily for 6 weeks.

tient and surgeon. Furthermore, with the growth of refractive IOLs, prevention of CME has become increasingly important. Although the efficacy of nepafenac 0.1% for anterior segment inflammation has been reported,^{11,12} its clinical usefulness in the treatment of CME and posterior segment inflammation has not yet been published. Preclinical evidence can provide several potential explanations for nepafenac's apparent advantage. First, nepafenac exhibits enhanced corneal permeability relative to diclofenac, allowing for greater intraocular drug accumulation.¹³ As already mentioned, the rate of hydrolysis of nepafenac to the more active amfenac is much greater in the retina/choroid (approximately 20 times) than in the iris/ciliary body.^{10,13} Finally, the administration of nepafenac also produces sustained inhibition of prostaglandin synthesis (a marker of inflammation) relative to a conventional NSAID (6 h vs. 20 min).¹⁰ The increased absorption, targeted activation, and greater duration of action of nepafenac may lead to improved efficacy in the posterior segment over other NSAIDs lacking these properties. In fact, support for this hypothesis can be found in a study of concanavalin A-induced retinal edema in rabbits, where nepafenac shows superior inhibition of retinal inflammation compared to either diclofenac or ketorolac.¹⁴

CONCLUSIONS

The cases presented in this paper suggest that nepafenac 0.1% has significant activity in treating CME. Nepafenac 0.1% not only reduced retinal thickness in these patients, but also restored visual acuity, with a mean improvement of 2.5 lines. While the ability of nepafenac 0.1% to successfully treat acute CME following cataract surgery is encouraging, what is more striking is its ability to resolve chronic CME, which had failed to respond to conventional NSAID/steroid therapy, as in patient #4. Also of interest is the positive effect of nepafenac on patient #7 who had DME, a condition that has historically been resistant to pharmacologic treatment. While case series cannot demonstrate a causal link between treatment and effect, these clinical data do strongly support the preclinical evidence suggesting that nepafenac 0.1% is a promising drug for the treatment of posterior segment inflammation, including CME. Moreover, the positive outcomes presented in this case series warrant further investigation of nepafenac 0.1% in a ran-

domized, controlled clinical trial in order to formally evaluate its ability to prevent and/or treat CME.

ACKNOWLEDGMENT

Research was supported by an unrestricted grant by the Research to Prevent Blindness Organization, New York, NY. This paper discusses the off-label use of nepafenac 0.1%.

REFERENCES

1. Montes, J., Erakgun, T., Afrashi, F., et al. Incidence of cystoid macular edema after uncomplicated phacemulsification. *Ophthalmologica* 217:408–412, 2003.
2. Rossetti, L., and Autelitano, A. Cystoid macular edema following cataract surgery. *Curr. Opin. Ophthalmol.* 11:65–72, 2000.
3. Schmier, J.K., Halpern, M.T., Covert, D.W., et al. Evaluation of costs for cystoid macular edema among patients after cataract surgery. *Retina* 27:621–628, 2007.
4. Flach, A.J., Jampol, L.M., Weinberg, D., et al. Improvement in visual acuity in chronic aphakic and pseudophakic cystoid macular edema after treatment with topical 0.5% ketorolac tromethamine. *Am. J. Ophthalmol.* 112:514–519, 1991.
5. Rho, D.S. Treatment of acute pseudophakic cystoid macular edema: Diclofenac versus ketorolac. *J. Cataract Refract. Surg.* 29:2378–2384, 2003.
6. Weisz, J.M., Bressler, N.M., Bressler, S.B., et al. Ketorolac treatment of pseudophakic cystoid macular edema identified more than 24 months after cataract extraction. *Ophthalmology* 106:1656–1659, 1999.
7. Miyake, K., Masuda, K., Shirato, S., et al. Comparison of diclofenac and fluorometholone in preventing cystoid macular edema after small incision cataract surgery: A multicentered, prospective trial. *Jpn. J. Ophthalmol.* 44:58–67, 2000.
8. Solomon, L.D. Efficacy of topical flurbiprofen and indomethacin in preventing pseudophakic cystoid macular edema [Flurbiprofen-CME Study Group I]. *J. Cataract Refract. Surg.* 21:73–81, 1995.
9. O'Brien, T.P. Emerging guidelines for use of NSAID therapy to optimize cataract surgery patient care. *Curr. Med. Res. Opin.* 21:1131–1137, 2005.
10. Gamache, D.A., Graff, G., Brady, M.T., et al. Nepafenac, a unique nonsteroidal prodrug with potential utility in the treatment of trauma-induced ocular inflammation: I. Assessment of anti-inflammatory efficacy. *Inflammation* 24:357–370, 2000.
11. Lane, S.S., Modi, S.S., Lehmann, R.P., et al. Nepafenac ophthalmic suspension 0.1% for the prevention and treatment of ocular inflammation associated with cataract surgery. *J. Cataract Refract. Surg.* 33:53–58, 2007. Erratum in: *J. Cataract Refract. Surg.* 33:564, 2007.

12. Lindstrom, R., and Kim, T. Ocular permeation and inhibition of retinal inflammation: An examination of data and expert opinion on the clinical utility of nepafenac. *Curr. Med. Res. Opin.* 22:397–404, 2006.
13. Ke, T.L., Graff, G., Spellman, J.M., et al. Nepafenac, a unique nonsteroidal prodrug with potential utility in the treatment of trauma-induced ocular inflammation: II. *In vitro* bioactivation and permeation of external ocular barriers. *Inflammation* 24:371–384, 2000.
14. Kapin, M.A., Yanni, J.M., Brady, M.T., et al. Inflammation-mediated retinal edema in the rabbit is inhibited by topical nepafenac. *Inflammation* 27:281–291, 2003.

Received: June 5, 2007
Accepted: July 23, 2007

Reprint Requests: Seenu M. Hariprasad
Department of Ophthalmology and Visual Science
University of Chicago
5841 South Maryland Avenue (MC 2114)
Chicago, IL 60637

E-mail: retina@uchicago.edu

